

Review

Electrodiagnostic criteria for diagnosis of ALS [☆]

Mamede de Carvalho ^a, Reinhard Dengler ^b, Andrew Eisen ^c, John D. England ^d,
Ryuji Kaji ^e, Jun Kimura ^f, Kerry Mills ^g, Hiroshi Mitsumoto ^h,
Hiroyuki Nodera ⁱ, Jeremy Shefner ^j, Michael Swash ^{k,*}

^a Department of Neurology, Hospital de Santa Maria, University of Lisbon, Lisbon, Portugal

^b Department of Neurology, Medizinische Hochschule Hannover, Germany

^c Department of Neurology, University of British Columbia, Vancouver, Canada

^d Department of Neurology, Billings Clinic, Billings, MT, USA

^e Department of Neurology, Tokushima University Graduate School of Medicine, Tokushima-city, Japan

^f Department of Neurology, University of Iowa, Iowa City, USA

^g Department of Neurology, Kings College Hospital, Guys Kings and St. Thomas's School of Medicine, London, UK

^h Eleanor and Lou Gehrig ALS Center, Neurological Institute, Columbia University, NY, USA

ⁱ Department of Neurology, Tokushima University, Tokushima-city, Japan

^j Department of Neurology, Upstate Medical University, Syracuse, NY, USA

^k Department of Neurology, Royal London Hospital, Queen Mary University of London, London, UK

See Editorial, pages 495–496

Abstract

A consensus meeting was held to determine the best use and interpretation of electrophysiological data in the diagnosis of ALS. The utility of needle EMG and nerve conduction studies was affirmed. It is recommended that electrophysiological evidence for chronic neurogenic change should be taken as equivalent to clinical information in the recognition of involvement of individual muscles in a limb. In addition, in the context of a suspected clinical diagnosis of ALS, fasciculation potentials should be taken as equivalent to fibrillation potentials and positive sharp waves in recognising denervation. The importance of searching for instability in fasciculation potentials and in motor unit potentials in ALS is stressed. These changes in the interpretation of electrophysiological data render obsolete the category Probable Laboratory-Supported ALS in the modified El Escorial diagnostic criteria for ALS. Methods for detection of upper motor neuron abnormality appear sensitive but require further study, particularly regarding their value when clinical signs of upper motor neuron lesion are uncertain.

© 2007 International Federation of Clinical Neurophysiology. Published by Elsevier Ireland Ltd. All rights reserved.

Keywords: Amyotrophic lateral sclerosis; Diagnosis; Electrophysiology; Electromyography; Motor neuron disease

1. Introduction

In the absence of an established biological marker ALS is primarily a clinical diagnosis (Li et al., 1991). In patients with generally increased reflexes, weak and wasted muscles in several body regions, a progressive history, often after a

focal onset, the diagnosis is readily established after appropriate imaging and other tests designed to exclude other possible diagnoses (Brooks, 1994, 2000). An experienced clinician may be virtually certain of the diagnosis in a patient with bilateral limb wasting, bilateral fasciculation in the tongue, or with wasting and hyperreflexia limited to a single limb, but none of these syndromes meet established criteria for a definite diagnosis of ALS (Beghi et al., 2002). Clinical neurophysiological examination is especially important in this context (de Carvalho et al., 2005), because it can extend the clinical findings by reveal-

[☆] Consensus of an International Symposium sponsored by IFCN, December 3–5 2006, Awaji-shima, Japan.

* Corresponding author. Tel.: +44 20 7638 3996; fax: +44 20 7638 4043.
E-mail address: mswash@btinternet.com (M. Swash).

ing lower motor neuron involvement in muscles in body regions otherwise regarded as unaffected. The electrophysiological features used in the diagnosis of ALS are based on the set of criteria proposed by Lambert (Lambert and Mulder, 1957; Lambert, 1969). An algorithm for utilizing electrophysiological data in diagnosis was incorporated in the revised El Escorial criteria for the diagnosis of ALS as Laboratory-Supported ALS (Brooks et al., 2000). However, as currently understood, EMG and clinical abnormalities cannot be combined in a single limb. Rather, the limb must be determined to be abnormal by one technique or the other.

Another factor that has limited the utility of clinical neurophysiology in the diagnosis of ALS is that current criteria require that muscles determined to be affected must show both ongoing denervation, defined by fibrillation potentials (fibs) or positive sharp waves (sw), and chronic partial reinnervation, implying reinnervation, defined by enlarged, frequently unstable motor units of increased duration, with a reduced interference pattern (Table 1). While the presence of active denervation and chronic denervation/reinnervation in the same muscle, although not specific for ALS, is diagnostically useful, many muscles do not show fibs-sw, so that the clinical neurophysiologist is left with insufficient findings to make the diagnosis of ALS (Behnia and Kelly, 1991; de Carvalho et al., 1999). In practice this is a significant problem; Traynor et al. (2000) found that, on current criteria, 22% of patients with ALS may die without reaching a level of diagnosis more certain than possible ALS.

It has become increasingly important to diagnose ALS early in the natural history of the disease, in order to arrange best management (Swash, 1998). It is intuitively likely that disease-modifying agents will be most successful when administered early, when a large population of motor neurons remains viable. Although specific disease modifying therapy is presently of limited efficacy, symptomatic treatments provide considerable benefit. In addition the pace of translational research in ALS promises an increasing number of experimental therapies, with opportunities to enter clinical trials.

2. Consensus symposium

In December 2006 an IFCN-sponsored consensus conference was convened on Awaji Island, Japan to consider how clinical neurophysiology could be employed more

effectively to facilitate early diagnosis (Swash, 2000). An evidence-based approach was used. The current Airlie House criteria (Brooks et al., 2000) were reviewed step by step in this process. In addition to established clinical techniques, a number of emerging methods were also evaluated, including motor unit number estimation (MUNE) and transcranial magnetic stimulation (TMS), a method of promise in the assessment of upper motor neuron lesion (Eisen and Swash, 2001). The role of EMG and nerve conduction studies in eliminating other diagnoses was reviewed. This review led us to make two recommendations for change in the way clinical neurophysiological information is used to contribute to the diagnosis of ALS that will impact on early diagnosis. These two changes are discussed below.

3. Conclusions of the consensus conference

1. We reaffirm the general principles underlying the El Escorial and Airlie House recommendations for the diagnosis of ALS. These are set out in modified form in Table 2. In particular, the importance of full nerve conduction studies and conventional EMG in excluding other diseases was recognised (Lambert, 1969; Behnia and Kelly, 1991; Daube, 2000). It is important to keep in mind that the clinical neurophysiological examination is used in the diagnosis of ALS when the diagnosis is suspected clinically – suggestive neurophysiological findings are therefore not intended to stand alone, outside the context of the clinical assessment.
2. We conclude that, since needle EMG is essentially an extension of the clinical examination in detecting features of denervation and reinnervation, the finding of neurogenic EMG changes in a muscle should have the same diagnostic significance as clinical features of neurogenic change in an individual muscle. Thus, within a single limb, we recommend that abnormalities required for the diagnosis of ALS may be derived from either clinical or neurophysiological study, thus constituting the requirement for involved muscles as set out in the general instructions (Table 2). This interpretation renders redundant the category “Laboratory Supported Probable ALS” (Table 2) and will facilitate earlier diagnosis,

Table 1
Criteria for detection of neurogenic change by needle EMG in the diagnosis of ALS (see also Table 4 for definitions of terms)

1. For the evaluation of LMN disease in ALS in any given body region clinical and electrophysiological abnormalities have equal diagnostic significance
2. EMG features of chronic neurogenic change must be found, for example
 - (a) MUPs of increased amplitude and increased duration, usually with an increased number of phases, as assessed by qualitative or quantitative studies
 - (b) Decreased motor unit recruitment, defined by rapid firing of a reduced number of motor units. In limbs affected by clinical features of significant UMN abnormalities, rapid firing may not be achieved
 - (c) Using a narrow band pass filter (500 Hz to 5 kHz) unstable and complex MUPs will be observed in most cases of ALS
3. In ALS fibs-sw are usually recorded in strong, non-wasted, muscles
4. In the presence of chronic neurogenic change on needle EMG in ALS, fasciculation potentials (FPs), preferably of complex morphology, are equivalent to fibrillations and positive sharp waves (fibs-sw) in their clinical significance

Table 2

Awaji-shima consensus recommendations for the application of electrophysiological tests to the diagnosis of ALS, as applied to the revised El Escorial Criteria (Airlie House 1998)

1. Principles (from the Airlie House criteria)

The diagnosis of amyotrophic lateral sclerosis [ALS] requires

(A) the presence of

- (1) evidence of *lower motor neuron (LMN) degeneration* by clinical, electrophysiological or neuropathological examination
- (2) evidence of *upper motor neuron (UMN) degeneration* by clinical examination; and
- (3) *progressive spread of symptoms or signs* within a region or to other regions, as determined by history, physical examination, or electrophysiological tests

(B) the absence of

- (1) *electrophysiological or pathological evidence of other disease processes* that might explain the signs of LMN and/or UMN degeneration, and
- (2) *neuroimaging evidence of other disease processes* that might explain the observed clinical and electrophysiological signs

2. Diagnostic categories

Clinically definite ALS is defined by *clinical or electrophysiological* evidence by the presence of LMN as well as UMN signs in the bulbar region and at least two spinal regions or the presence of LMN and UMN signs in three spinal regions

Clinically probable ALS is defined on *clinical or electrophysiological* evidence by LMN and UMN signs in at least two regions with some UMN signs necessarily rostral to (above) the LMN signs

Clinically possible ALS is defined when *clinical or electrophysiological* signs of UMN and LMN dysfunction are found in only one region; or UMN signs are found alone in two or more regions; or LMN signs are found rostral to UMN signs. Neuroimaging and clinical laboratory studies will have been performed and other diagnoses must have been excluded

These recommendations emphasize the equivalence of clinical and electrophysiological tests in establishing neurogenic change in bodily regions. The category of “Clinically Probable Laboratory-Supported ALS” is rendered redundant.

since it will allow a limb to be classified as abnormal earlier than if this decision is based on clinical or EMG criteria alone. The essential change is thus to recognise a neurogenic EMG abnormality (Table 1) as of equivalent significance to the clinical abnormality. It is, nonetheless, important to confirm that EMG evidence of neurogenic abnormality is found in clinically weak muscles.

3. We recognise that muscles may show evidence of chronic neurogenic change in the absence of fibs-sw. We therefore propose that the presence of fasciculation potentials (FPs) in a muscle identified as showing needle EMG features of neurogenic change should serve as evidence of ongoing denervation, equivalent in importance to fibs-sw. This criterion would obviate the need for the often difficult search for fibs-sw in patients with clinically evident features of ALS; in particular, in cranial-innervated muscles and muscles of normal bulk and strength. For example, although Finsterer et al. (1998) recorded fibs-sw in some patients in bulbar muscles, de Carvalho et al. (1999) found no fibs-sw in bulbar muscles in 15 bulbar-onset patients; fibs-sw were found in limb muscle in only 7 of these 15 patients. In addition, in 2 of 28 newly diagnosed upper limb onset ALS patients, fibs-sw were absent in the weak upper limb.

4. Benign and neurogenic fasciculations

Although FPs have long been recognised as a characteristic feature of ALS, they can be seen in normal muscles (benign fasciculations) and they are not invariably noted in all muscles in ALS patients. However, there are certain features of FPs in ALS that confirm their importance and allow them to be distinguished from benign FPs. FPs

associated with neurogenic disease, especially ALS, show a complex morphology, and often exhibit instability when studied with a high band pass filter and a trigger delay line, which reveals increased jitter with blocking of some components, indicating their origin from reinnervated motor units (Janko et al., 1989; de Carvalho and Swash, 1997). Although particularly characteristic of ALS, unstable FPs also occur in other progressive neurogenic disorders. In contrast, those seen in healthy muscles (benign fasciculations) are simple in morphology, are stable and are always recorded in the context of normal voluntarily activated MUPs. FPs therefore have a clear and relevant impact on the diagnosis of ALS, a feature long recognised in clinical neurology.

It is obvious that ALS cannot be diagnosed purely on the basis of a finding of FPs. Thus FPs only achieve diagnostic significance for ALS in the context of a clinically suspected diagnosis. Stable FPs of simple morphology occur in benign conditions, and FPs of complex morphology occur in many other neurogenic conditions (Rosenfeld, 2000). The occurrence of FPs in other neurogenic disorders, for example in peripheral neuropathies, is an example of the importance of clinical context in diagnosis. This lack of specificity applies also to the presence of fibs-sw. While fibs-sw are never a benign finding they are found in any disease in which there is denervation or muscle damage. However, when FPs and/or fibs-sw are found in conjunction with chronic neurogenic abnormalities, in the context of a diffuse or root-related disorder with superimposed upper motor neuron signs, they assume critical significance and suggest ALS as the diagnosis. We conclude that FPs and fibs-sw have similar and equivalent importance in diagnosis in ALS. We recognise a theoretical possibility that utilizing FPs in this way in the diagnostic process may decrease the

diagnostic specificity that a muscle is affected by ALS, but we note that the evidence suggests that this change in diagnostic criteria, applied to the existing Airlie House criteria, would allow patients to be appropriately diagnosed earlier in their disease course, so providing diagnostic clarity for those patients, who may be severely affected by the disease, but do not currently meet accepted EMG diagnostic criteria. We note also that, in general, abnormal spontaneous activity persists in weak muscles throughout the disease course.

Finally, we stress that, since there is as yet no specific diagnostic test for ALS (Pradat et al., 2007), it is wise to reassess a diagnosis of ALS during the disease course, especially if there are any atypical features, or lack of progression.

5. Evidence that FPs are equivalent to fibs-sw

FPs may originate within the lower motor neuron at almost any location but, in ALS, FPs most commonly arise distally, often in the region of the distal axonal arborisation (Wettstein, 1979; Roth, 1982, 1984). In normal subjects the site of origin of FPs may be distal or proximal. These findings were confirmed by de Carvalho and Swash (1997), who found that, late in the course of ALS, FPs arose distally, and that their morphology was complex and often unstable. These observations suggest that damaged axons are involved in the origin of FPs. Fibs-sw arise from denervated muscle fibres but, like complex, unstable FPs in ALS, they arise in the context of active denervation, with dysfunction in the terminal arborisation. Unstable FPs are not a feature of Kennedy's disease, a less rapidly progressive disease (Hirota et al., 2000), again pointing to the distal axon as the usual site of origin of FPs in ALS. Threshold tracking studies also suggest a distal origin for FPs in ALS. In ALS sodium conductance is increased and potassium conductance is decreased (Kanai et al., 2006). These changes result in axonal hyperexcitability, which may contribute to the generation of FPs. Although this abnormality does not clearly localise to the distal axon, it does suggest an axonal rather than a cell body process as the site of abnormality, and it is consistent with the proposition that FPs in ALS signify ongoing axon damage. In distally predominant neurogenic disorders, e.g., peripheral neuropathies, FPs also occur, with large reinnervated MUPs. The clinical context, and the presence of abnormalities in motor and sensory conduction velocity studies are important in diagnostic interpretation, since neither FPs nor fibs-sw are specific to ALS, but also occur in focal and generalised neuropathies (Kimura, 2001) and fibs-sw may also occur in acute dermatomyositis (Kimura, 2001).

6. Unstable MUPs and other needle EMG considerations

The electrophysiological abnormalities necessary to conclude that a muscle under study has undergone chronic denervation–reinnervation (Table 1) have been addressed

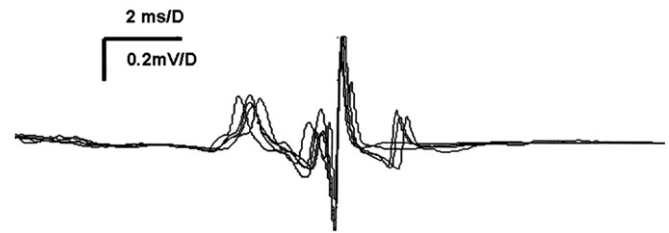


Fig. 1. Unstable MUP in a patient with ALS. There is increased “jiggle” of several components of the MUP, and impulse blocking of the last component. Concentric needle EMG recording with trigger delay line, using 500 Hz low band pass filter.

in detail in previous discussions of criteria for the diagnosis of ALS (Lambert, 1969; Behnia and Kelly, 1991; Daube, 2000; de Carvalho and Swash, 2006). However, a finding that can also provide useful information that has not been fully recognised is motor unit instability (Schwartz and Swash, 1982; Stalberg and Sonoo, 1994). Motor unit instability (Fig. 1) is noted when a single MUP is studied with a trigger delay line, so that the morphology of individual units can be studied during a continuous firing train. In such recordings it is frequently noted that subunits of a MUP drop in and out of the recording (impulse blocking) as well as showing enhanced jitter (Stalberg et al., 1975; Swash and Schwartz, 1982). These observations may be enhanced during concentric needle EMG recordings by increasing the low pass filter setting to 500 Hz or even to 5 kHz, which accentuates recognition of the high frequency nature of this instability (Payan, 1978; Stalberg and Sonoo, 1994). While the detection of unstable MUPs is not a requirement for the electrophysiological diagnosis of ALS, and is not specific for ALS, it is helpful and informative, since it is a characteristic feature of progressive denervation occurring in reinnervated motor units, and is especially important in the EMG assessment of suspected ALS. In ALS giant monophasic notched potentials, with prominent satellite potentials, probably representing end-stage neurogenic change, may also be found.

7. Choice of muscles for needle EMG evaluation

There are a number of studies indicating the utility of muscles not commonly studied in neuromuscular disease; for example, bulbar muscles (Finsterer et al., 1998; Cappelari et al., 1999); facial muscles (Bir et al., 2006); tongue (Finsterer et al., 1997); masticatory muscles (Preston et al., 1997); thoracic paraspinal muscles (Kuncl et al., 1988; Kyuno et al., 1996); and rectus abdominis muscles (Xu et al., 2007). These can be useful adjunctive muscles when it is important to find evidence of involvement of additional body regions.

8. Nerve conduction studies

Clinical neurophysiology has an essential role in diagnosis, in eliminating other lower motor neuron disorders that may resemble ALS. This is accomplished primarily through

nerve conduction studies. We confirmed the utility of such studies and concurred with prior established criteria for their application and interpretation (Lambert, 1969; Behnia and Kelly, 1991; Daube, 2000; Brooks et al., 2000; de Carvalho and Swash, 2006) as summarised in Table 3. In testing for conduction block we emphasize that physiological temporal dispersion gives rise to a linear reduction in amplitude and area of the CMAP (and SNAP amplitudes) evoked by proximal compared with distal stimulation, that is especially evident when three stimulation sites are used. A non-linear reduction (an assessment that requires three stimulation sites) in amplitude or area of the proximally evoked CMAP suggests a peripheral nerve lesion; if this is associated with pathological temporal dispersion a demyelinating nerve lesion is likely, even in the absence of conduction block (Kimura, 2001).

9. Electrophysiological evaluation of upper motor neuron (UMN) dysfunction

The diagnosis of ALS requires demonstration of a combination of upper and lower motor neuron abnormalities whether by clinical or electrophysiological criteria, as set out in the Airlie House consensus recommendations (Table 1). Although it has been hoped that TMS might prove a sensitive test for upper motor neuron involvement in ALS (Eisen and Weber, 2000) this has not been confirmed in the published studies, at least not for patients with clinically missing or equivocal upper motor neuron signs, and expert opinions (Ziemann and Eisen, 2004) are equivocal. Central motor conduction time (CMCT), however, is frequently prolonged to muscles of at least one extremity (Kobayashi and Pascual Leone, 2003; Rossini and Rossi, 1998, 2007). More complex stimulation paradigms have not been helpful in diagnosis of ALS (Eisen and Swash, 2001) except for short-interval, paired-pulse stimulation, which revealed reduced intracortical inhibition (Ziemann et al., 1997). However, this technique is not practical and therefore not widely used, and experience in early ALS, the crucial time for diagnosis, is limited. A relatively new TMS technique, the triple stimulation method, has shown

a high sensitivity to detect upper motor neuron dysfunction in ALS and yielded abnormal results also in early stages of the disease in two laboratories (Magistris et al., 1999; Komissarow et al., 2004; Rösler and Magistris, 2004). Confirmation of these results from wider application in other laboratories is required.

Developments in magnetic resonance imaging of brain tracts may yet prove helpful, although this has not so far been demonstrated, and the methodology is complex and expensive.

9.1. Transcranial magnetic stimulation (TMS)

TMS requires that the target muscle have a detectable CMAP. The following features suggest abnormality of upper motor neuron function:

1. Increased central motor conduction time (CMCT).
2. Increased absolute latency to a tested muscle, provided that distal motor conduction slowing can be excluded.
3. In patients with bulbar onset disease, an absent response to TMS in a limb is supportive of upper motor neuron lesion.
4. The triple stimulation technique has proven sensitive in detecting impairment of upper motor neuron function in the early stages of the disease as well as later in the disease course (Komissarow et al., 2004; Rösler and Magistris, 2004). However, experience with this promising test is so far relatively limited.

9.2. Other techniques for UMN disorder

F-wave studies, including *F/M* amplitude ratios (Drory et al., 2001; Argyriou et al., 2006), may be useful. Abnormally reduced firing frequencies in a wasted muscle may occur with UMN lesion (Dorfman et al., 1989), but the sensitivity of this abnormality, especially in heavily reinnervated units, is uncertain.

Developments in magnetic resonance imaging of brain tracts may yet prove helpful (Mitsumoto et al., 2007),

Table 3
Use of nerve conduction studies in ALS: exclusion of other disorders

The following are compatible with ALS:
1. Normal SNAP amplitude and sensory conduction velocities (CV) in the absence of concomitant entrapment or other neuropathies. Mildly reduced SNAP amplitudes and CVs in the presence of neuropathy of identified aetiology are acceptable
2. Motor CV >75% of the lower limit of normal, and minimum <i>F</i> -wave latency <130% of the upper limit of normal
3. Distal CMAP latency and duration <150% of normal
4. Absence of conduction block (CB) and of pathological temporal dispersion, as defined by baseline-negative CMAP area reduction on proximal versus distal stimulation >50% when distal baseline-negative peak CMAP amplitude is large enough to allow such assessment (usually >1 mV). A proximal negative peak CMAP duration <30% of the distal value suggests CB

Table 4
Electrophysiological definitions

<i>Complex FPs</i> : one feature of polyphasic (>4 phases), increased duration, or increased amplitude compared to normal values for MUPs in the muscle studied. Complex FPs may be unstable (Fig. 1)
<i>Fibs-sw</i> : (AANEM definition) duration <5 ms, amplitude <1 mV, discharge frequency 1–50 Hz
<i>Unstable MUPs</i> : use low band pass filter setting >500 Hz; superimpose sequence of consecutive motor unit discharges, and look for increased jitter (jiggle) and impulse blocking (Payan, 1978; Stalberg and Sonoo, 1994)
<i>Chronic neurogenic change</i> : MUPs of increased duration, increased amplitude, and often with increased phases. A decreased interference pattern characterised by increased firing rate of remaining motor units, and increased envelope amplitude of the interferential pattern

although this has not so far been demonstrated, and the methodology is complex and expensive.

9.3. Comment on UMN tests

The need for a reliable and sensitive physiological method for assessing UMN disorder is evident by the controversy that often surrounds interpretation of apparently hyperactive tendon reflexes in wasted muscles in patients with a suspected diagnosis of ALS. Electrophysiological assessment of the upper motor neuron is therefore likely to be important but current methods require more general application before their limitations can be assessed.

Acknowledgements

The meeting was generously sponsored by IFCN and was organized by R. Kaji and A. Eisen. This work was also supported by research grants from the Japanese Ministry of Education, Science, Culture and Sports (Centre of Excellence or COE grant) and Ministry of Health, Welfare and Labour. The work was in part supported by grants from Eisai Pharmaceutical Co., Nihon Pharmaceutical Co., Takeda Pharmaceutical Co., Mitsubishi WelPharma Co. and Astelas Pharma Co.

References

- Argyriou AA, Polychronopoulos P, Talelli P, Chroni E. F-wave study in amyotrophic lateral sclerosis: assessment of balance between upper and lower motor neuron involvement. *Clin Neurophysiol* 2006;117:1260–5.
- Behnia M, Kelly J. Role of electromyography in amyotrophic lateral sclerosis. *Muscle Nerve* 1991;14:1236–41.
- Beghi E, Balzarini C, Bogliun G, Logroschino G, Manfredi L, Mazzini L, et al. Reliability of the El Escorial diagnostic criteria for amyotrophic lateral sclerosis. *Neuroepidemiology* 2002;21:265–70.
- Bir LS, Acar G, Kilincer A. EMG findings of facial muscles in ALS. *Clin Neurophysiol* 2006;117:476–8.
- Brooks BR and World Federation of Neurology Sub-Committee on Motor Neuron Diseases. El Escorial WFN criteria for the diagnosis of amyotrophic lateral sclerosis. *J Neurol Sci* 1994;124:965–1085.
- Brooks BR, Miller RG, Swash M, Munsat TL for the World Federation of Neurology Research Group on Motor Neuron Diseases. El Escorial revisited: revised criteria for the diagnosis of amyotrophic lateral sclerosis. *ALS* 2000;1:293–300.
- Cappellari A, Brioschi A, Barbieri SS, Braga M, Scarlato G, Dilani V. A tentative interpretation of electromyographic regional differences in bulbar and limb onset ALS. *Neurology* 1999;52:644–6.
- Daube JR. Electrodiagnostic studies in amyotrophic lateral sclerosis and other motor neuron disorders. *Muscle Nerve* 2000;23:1488–502.
- de Carvalho M, Swash M. Fasciculation potentials: a study of amyotrophic lateral sclerosis and other neurogenic disorders. *Muscle Nerve* 1997;21:336–44.
- de Carvalho M, Swash M. Conventional clinical neurophysiology in ALS. In: Brown R, Pasinelli P, Swash M, editors. *Amyotrophic lateral sclerosis*. 2nd ed. London: Informa Healthcare; 2006. p. 105–24.
- de Carvalho M, Bentes C, Evangelista T, Sales-Luis M. Fibrillation and sharp-waves: do we need them to diagnose ALS? *ALS* 1999;1:29–32.
- de Carvalho M, Chio A, Dengler R, Hecht M, Weber M, Swash M. Neurophysiological measures in amyotrophic lateral sclerosis: markers of progression in clinical trials. *ALS* 2005;6:17–29.
- Dorfman LJ, Howard JE, McGill KC. Motor unit firing rates and firing rate variability in the detection of neuromuscular disorders. *Electroencephalogr Clin Neurophysiol* 1989;73:215–24.
- Drory VE, Kovach I, Groozman GB. Electrophysiologic evaluation of the upper motor neuron involvement in amyotrophic lateral sclerosis. *ALS* 2001;2:147–52.
- Eisen A, Swash M. Clinical neurophysiology of ALS. *Clin Neurophysiol* 2001;112:2190–201.
- Eisen A, Weber M. Neurophysiological evaluation of cortical function in the early diagnosis of ALS. *ALS* 2000;1(Suppl. 1):S47–51.
- Finsterer J, Erdorf M, Mamoli B, Fuglsang-Frederiksen A. Needle electromyography of bulbar muscles in patients with amyotrophic lateral sclerosis: evidence of subclinical involvement. *Neurology* 1998;51:1417–22.
- Finsterer J, Fuglsang-Frederiksen A, Mamoli B. Needle EMG of the tongue: motor unit action potential versus peak ratio analysis in limb and bulbar onset amyotrophic lateral sclerosis. *J Neurol Neurosurg Psychiatry* 1997;63:175–80.
- Hirota N, Eisen A, Weber M. Complex fasciculations and their origin in amyotrophic lateral sclerosis and Kennedy's disease. *Muscle Nerve* 2000;23:1872–5.
- Janko M, Trontelj JV, Gersak K. Fasciculations in motor neuron disease: discharge rate reflects extent and recency of collateral sprouting. *J Neurol Neurosurg Psychiatry* 1989;52:1375–81.
- Kanai K, Kuwabara S, Misawa S, Tamura N, Ogawara K, Nakata M, et al. Altered axonal excitability properties in amyotrophic lateral sclerosis: impaired potassium channel function related to disease stage. *Brain* 2006;129:953–62.
- Kimura J. *Electrodiagnosis in diseases of nerve and muscle*. Oxford: Oxford University Press; 2001. pp. 79.
- Kobayashi M, Pascual Leone A. Transcranial magnetic stimulation in neurology. *Lancet Neurol* 2003;2:145–56.
- Komissarov L, Rollnik JD, Bogdanova D, Krampfl K, Khabirov FA, Kossev A, et al. Triple stimulation technique (TST) in amyotrophic lateral sclerosis. *Clin Neurophysiol* 2004;115:356–60.
- Kyuno K, Ito H, Saito T, Kowa H, Tachibana S. Needle electromyography in the thoracic paraspinal muscles in motor neuron disease. *No To Shinkei* 1996;48:637–42.
- Kuncl RW, Cornblath DR, Griffin JW. Assessment of thoracic paraspinal muscles in the diagnosis of ALS. *Muscle Nerve* 1988;11:484–92.
- Lambert EH, Mulder DW. Electromyographic studies in amyotrophic lateral sclerosis. *Mayo Clin Proc* 1957;32:441–6.
- Lambert EH. Electromyography in amyotrophic lateral sclerosis. In: Norris FH, Kurland LT, editors. *Motor neuron diseases: research in amyotrophic lateral sclerosis and related disorders*. New York: Grune and Stratton; 1969. p. 135–53.
- Li TM, Swash M, Alberman E, Day SJ. Diagnosis of motor neuron disease by neurologists: a study in three countries. *J Neurol Neurosurg Psychiatry* 1991;54:980–3.
- Magistris MR, Rosler KM, Truffert A, Landis T, Hess CW. A clinical study of motor evoked potentials using a triple stimulation technique. *Brain* 1999;122:265–79.
- Mitsumoto H, Ulug AN, Pullman SL, Gooch CL, Chan S, Tang M-X, et al. Quantitative objective markers for upper and lower motor neuron dysfunction in ALS. *Neurology* 2007;68:1402–10.
- Payan J. The blanket principle: a technical note. *Muscle Nerve* 1978;1:423–6.
- Pradat PF, Bruneteau G, Gonzalez de Aguilar J-L, Dupuis L, Jkic N, Salachas F, et al. Muscle Nogo-A expression is a prognostic marker in lower motor neuron syndromes. *Ann Neurol* 2007;62:15–20.
- Preston DC, Shapiro BE, Raynor EM, Kothari MJ. The relative value of facial, glossal and masticatory muscles in the electrodiagnosis of amyotrophic lateral sclerosis. *Muscle Nerve* 1997;20:370–2.
- Rosenfeld J. Fasciculations without fibrillation: the dilemma of early diagnosis. *ALS* 2000;1(Suppl. 1):S53–6.
- Rösler KM, Magistris MR. Triple stimulation technique (TST) in amyotrophic lateral sclerosis. *Clin Neurophysiol* 2004;115:1715.

- Rossini PM, Rossi S. Transcranial magnetic stimulation: diagnostic, therapeutic, and research potential. *Clin Neurophysiol* 1998;106:180–94.
- Rossini PM, Rossi S. Transcranial magnetic stimulation: diagnostic, therapeutic and research potential. *Neurology* 2007;68:484–8.
- Roth G. The origin of fasciculations. *Ann Neurol* 1982;12:542–54.
- Roth G. Fasciculations and their F-response: localization of their axonal origin. *J Neurol Sci* 1984;63:299–306.
- Schwartz MS, Swash M. A longitudinal study of changes in motor units in motor neuron disease. *J Neurol Sci* 1982;56:185–97.
- Stalberg E, Schwartz MS, Trontelj JV. *J Neurol Sci* 1975;24:403–15.
- Stalberg E, Sonoo M. Assessment of variability in the shape of the motor unit action potential: the “jiggle” at consecutive discharges. *Muscle Nerve* 1994;17:1135–44.
- Swash M. Early diagnosis of ALS/MND. *J Neurol Sci* 1998;Suppl. 1:S33–6.
- Swash M. Shortening the time to diagnosis in ALS: the role of electrodiagnostic studies. *ALS* 2000;1(Suppl.):S67–72.
- Swash M, Schwartz MS. A longitudinal study of changes in motor units in motor neurone disease. *J Neurol Sci* 1982;52:185–97.
- Traynor BJ, Codd MB, Corr B, Forde C, Frost E, Hardiman OM. Clinical features of amyotrophic lateral sclerosis according to the El Escorial criteria and Airlie House diagnostic criteria. *Arch Neurol* 2000;57:1171–6.
- Wettstein A. The origin of fasciculations in motoneuron disease. *Ann Neurol* 1979;5:295–300.
- Xu Y, Zheng J, Zhang S, Kang D, Zhang J, Fan D. Needle electromyography of the rectus abdominis in patients with amyotrophic lateral sclerosis. *Muscle Nerve* 2007;35:383–5.
- Ziemann U, Eisen A. TMS for ALS: why and why not. *Clin Neurophysiol* 2004;115:1237–8.
- Ziemann U, Winter M, Reimers CD, Reimers K, Tergau F, Paulus W. Impaired motor cortex inhibition in patients with amyotrophic lateral sclerosis. Evidence from paired transcranial magnetic stimulation. *Neurology* 1997;49:1292–8.